Face antérieure de la cuisse: plan vasculo-nerveux

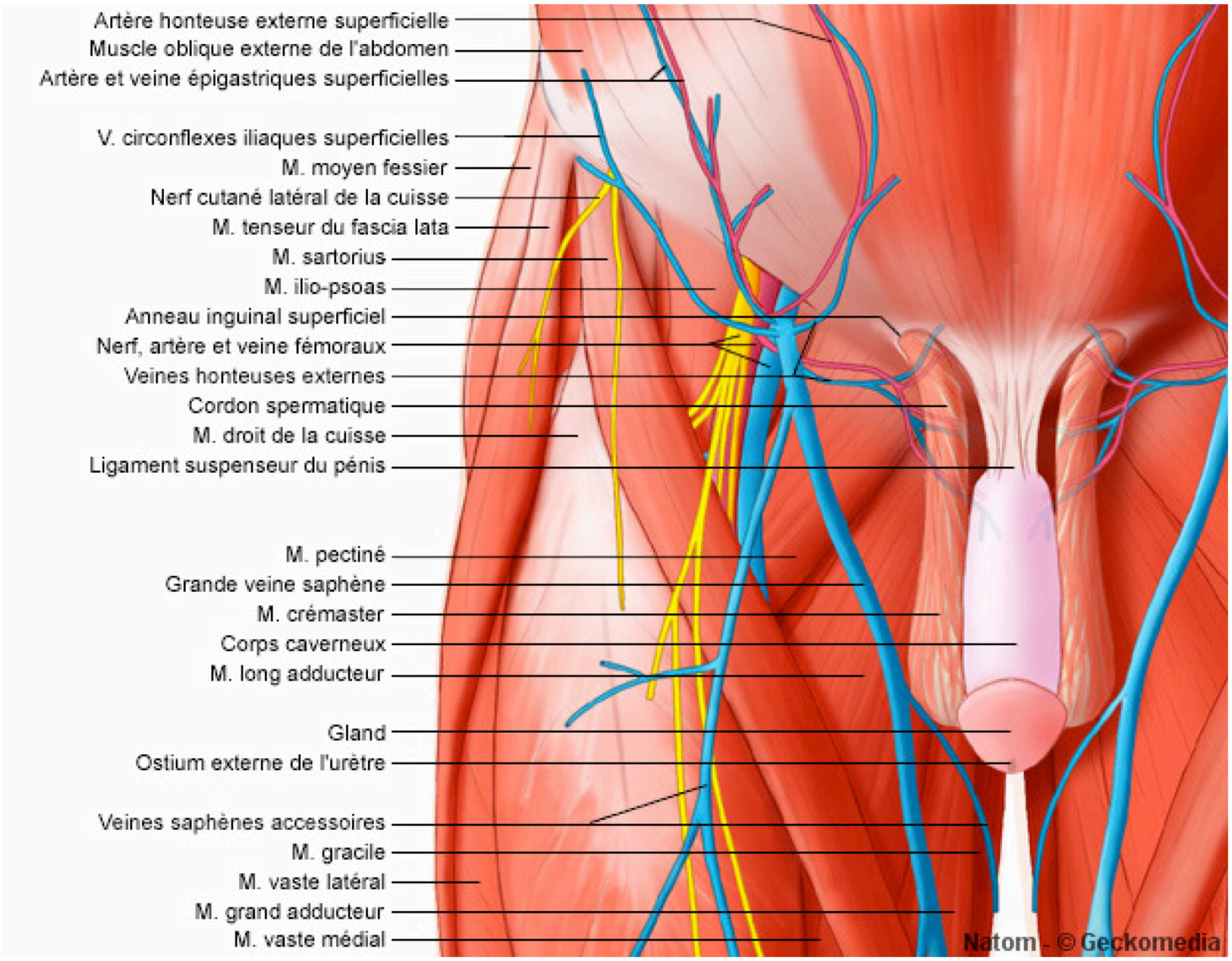

© Jules Boone 2005